

Beta-oscillations in the posterior hypothalamus are associated with spontaneous cluster headache attack

Wido Nager · Thomas F. Münte · Josep Marco-Pallares · Marcus Heldmann · Reinhard Dengler · Hans Holger Capelle · Götz Lütjens · Joachim K. Krauss

Received: 27 June 2009 / Revised: 13 April 2010 / Accepted: 29 April 2010 / Published online: 14 May 2010
© Springer-Verlag 2010

Dear Sirs,

The etiology of chronic cluster headache (CH), manifesting as episodes of severe head pain with cranial autonomic features is still unknown, but a central role of the hypothalamus has been discussed recently. For example, during acute CH attacks (but not during migraine) PET revealed activation of the ipsilateral posterior inferior hypothalamus (PIH) [9]. In addition, increased grey matter density of the ipsilateral PIH has been found [7, 8]. These findings have prompted the use of deep brain stimulation (DBS) of the ipsilateral PIH in CH, which has been shown to be a promising option in cases refractory to other therapies.

W. Nager · T. F. Münte (✉) · J. Marco-Pallares
Department of Neuropsychology, University of Magdeburg,
P.O. Box 4120, 39106 Magdeburg, Germany
e-mail: thomas.muente@neuro.uni-luebeck.de

W. Nager · R. Dengler
Department of Neurology, Medical School Hannover,
30623 Hannover, Germany

T. F. Münte
Department of Neurology, University of Lübeck,
Lübeck, Germany

J. Marco-Pallares
Department of Ciències Fisiològiques, Faculty of Medicine,
Campus de Bellvitge, IDIBELL, University of Barcelona,
08907 Barcelona, Spain

M. Heldmann
Department of Neurology, University of Magdeburg,
39106 Magdeburg, Germany

H. H. Capelle · G. Lütjens · J. K. Krauss
Department of Neurosurgery, Medical School Hannover,
30623 Hannover, Germany

Currently available series suggest that the procedure is working in about 50% of operated patients [1, 6].

While suggestive, the previously described structural and functional changes of the PIH in CH leave open the question as to the neural events that precipitate and mediate spontaneous CH attacks within the hypothalamus. Spontaneous discharge properties of hypothalamic neurons have been characterized by intraoperative microelectrode recordings to be dominated by 25 Hz oscillations outside of active cluster episodes [3, 4]. In addition, a recent report described changes of local field potentials (LFP) recorded from a DBS electrode during an acute attack [2] with a power increase at 20 Hz at the onset of the attack. Here, we extend this observation with data from an additional case. A 52 year old man had suffered from right-sided chronic CH since age 41 and had received prolonged but unsuccessful courses of all standard treatments (including oxygen, sumatriptan, verapamil, corticosteroids). The target in the PIH was defined by CT-stereotactic surgery refined by microelectrode recording. The DBS electrode (Medtronic model 3389) was externalized for several days for test stimulation. Bipolar recordings (1,000 pts/s) between the two contacts with the greatest distance as well as surface EEG activity were obtained. During a recording session (no stimulation) the patient complained about an acute severe right-sided CH episode accompanied by slight ipsilateral ptosis but no conjunctival ingestion. Coinciding with the onset of the attack, the LFP spectrum showed a pronounced peak at 20 Hz (see Figs. 1a and 2). There was no such activity in the scalp recordings (Fig. 1b). Only one attack was observed. DBS led to marked initial clinical improvement (90% decrease of attack frequency) followed by a gradual increase of attack frequency (to ~50% of baseline) at 2 year follow-up.

The present case is similar to one reported by Brittain and colleagues [2] who found a prominent peak in the LFP spectra around 16–22 Hz at the onset of an attack. The

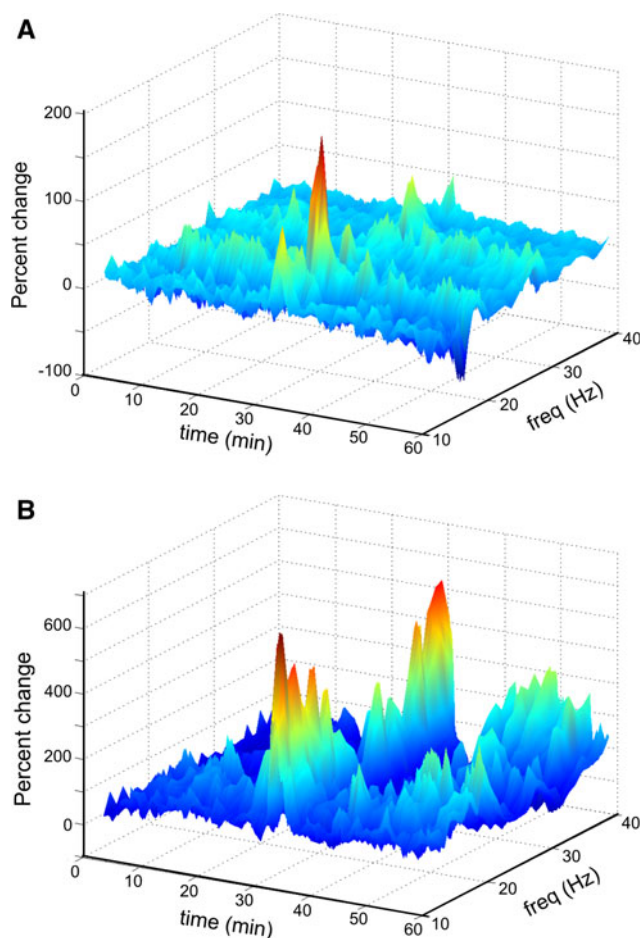


Fig. 1 **a** Upper panel displays the continuous LFP power spectra from the PIH. Fast Fourier transform for sequential time-windows of 10 s each. For each frequency, the power of the actual sample was calculated as percent change relative to a 100 s baseline. Shown is a bipolar derivation between contacts 0 and 3 of the DBS electrode. At time 30 min the patient reported an acute onset cluster headache which was paralleled by a strong increase in activity at 20 Hz. **b** Data from a surface electrode Cz (referenced to an electrode on the right mastoid process). At the onset of the attack, a power increase at lower frequencies as well as high frequency activity (related to EMG artefacts) is seen

high-power oscillations were present only for several minutes and thus seem to be involved in the initial development of the attack. For example, they could be involved in hypothalamic triggering of the trigeminoautonomic reflex. Together with the finding of Bartsch et al. [1] who reported triggering of a CH attack by 130 Hz stimulation these results argue for a hypothalamic role in the initial phase of CH, but it can not be ruled out, of course, that the hypothalamic activity is controlled by other brain areas. Indeed, the current hypothesis of increased neural hypothalamic activity, a major site for the regulation of biological rhythms, better accounts for the syndrome's rhythmic character than recent proposals of a particular vascular or inflammatory pathophysiology. Since CH

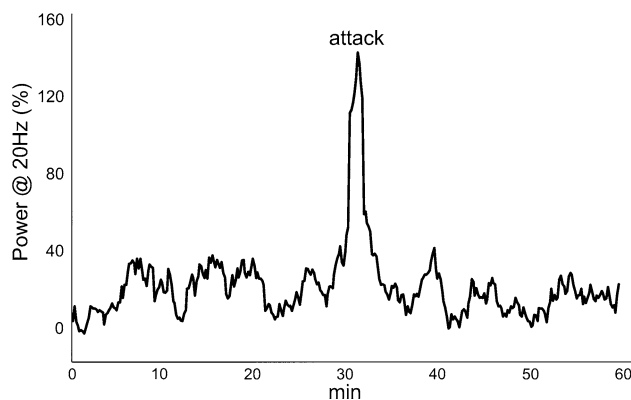


Fig. 2 Shown are power-changes over time at 20 Hz. A marked increase of power coincides with the onset of the attack

attacks are reliably triggered by nitroglycerin [5, 10], such attacks may be further explored during LFP recordings to optimize target selection and to learn more about the origin of cluster headache attacks.

References

- Bartsch T, Pinsker MO, Rasche D, Kinfe T, Hertel F, Diener HC, Tronnier V, Mehdorn HM, Volkmann J, Deuschl G, Krauss JK (2008) Hypothalamic deep brain stimulation for cluster headache: experience from a new multicase series. *Cephalalgia* 28:285–295
- Brittain JS, Green AL, Jenkinson N, Ray NJ, Holland P, Stein JF, Aziz TZ, Davies P (2009) Local field potentials reveal a distinctive neural signature of cluster headache in the hypothalamus. *Cephalalgia* 29(11):1165–1173
- Broggi G, Franzini A, Leone M, Bussone G (2007) Update on neurosurgical treatment of chronic trigeminal autonomic cephalalgias and atypical facial pain with deep brain stimulation of posterior hypothalamus: results and comments. *Neurol Sci* 28(Suppl 2):S138–S145
- Cordella R, Carella F, Leone M, Franzini A, Broggi G, Bussone G, Albanese A (2007) Spontaneous neuronal activity of the posterior hypothalamus in trigeminal autonomic cephalalgias. *Neurol Sci* 28:93–95
- Hannerz J, Greitz D (1992) MRI of intracranial arteries in nitroglycerin induced cluster headache attacks. *Headache* 32:485–488
- Leone M, Proietti CA, Franzini A, Broggi G, Cortelli P, Montagna P, May A, Juergens T, Cordella R, Carella F, Bussone G (2008) Lessons from 8 years' experience of hypothalamic stimulation in cluster headache. *Cephalalgia* 28:787–797
- May A (2009) Morphing voxels: the hype around structural imaging of headache patients. *Brain* 132:1419–1425
- May A, Ashburner J, Buchel C, McGonigle DJ, Friston KJ, Frackowiak RS, Goadsby PJ (1999) Correlation between structural and functional changes in brain in an idiopathic headache syndrome. *Nat Med* 5:836–838
- May A, Goadsby PJ (1999) The trigeminovascular system in humans: pathophysiologic implications for primary headache syndromes of the neural influences on the cerebral circulation. *J Cereb Blood Flow Metab* 19:115–127
- Sances G, Tassorelli C, Pucci E, Ghiotto N, Sandrini G, Nappi G (2004) Reliability of the nitroglycerin provocative test in the diagnosis of neurovascular headaches. *Cephalalgia* 24:110–119